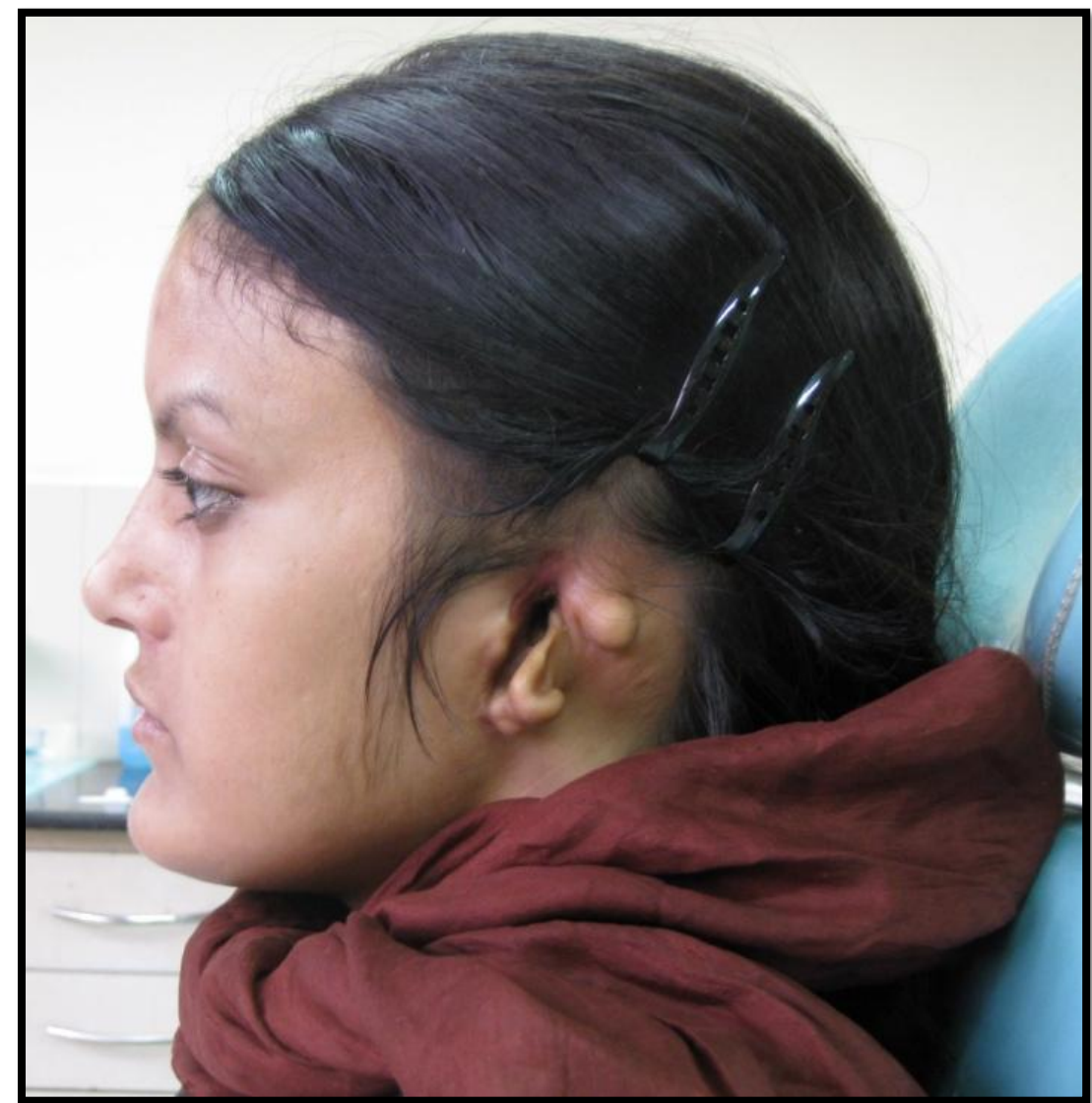

# Rehabilitation of lost face

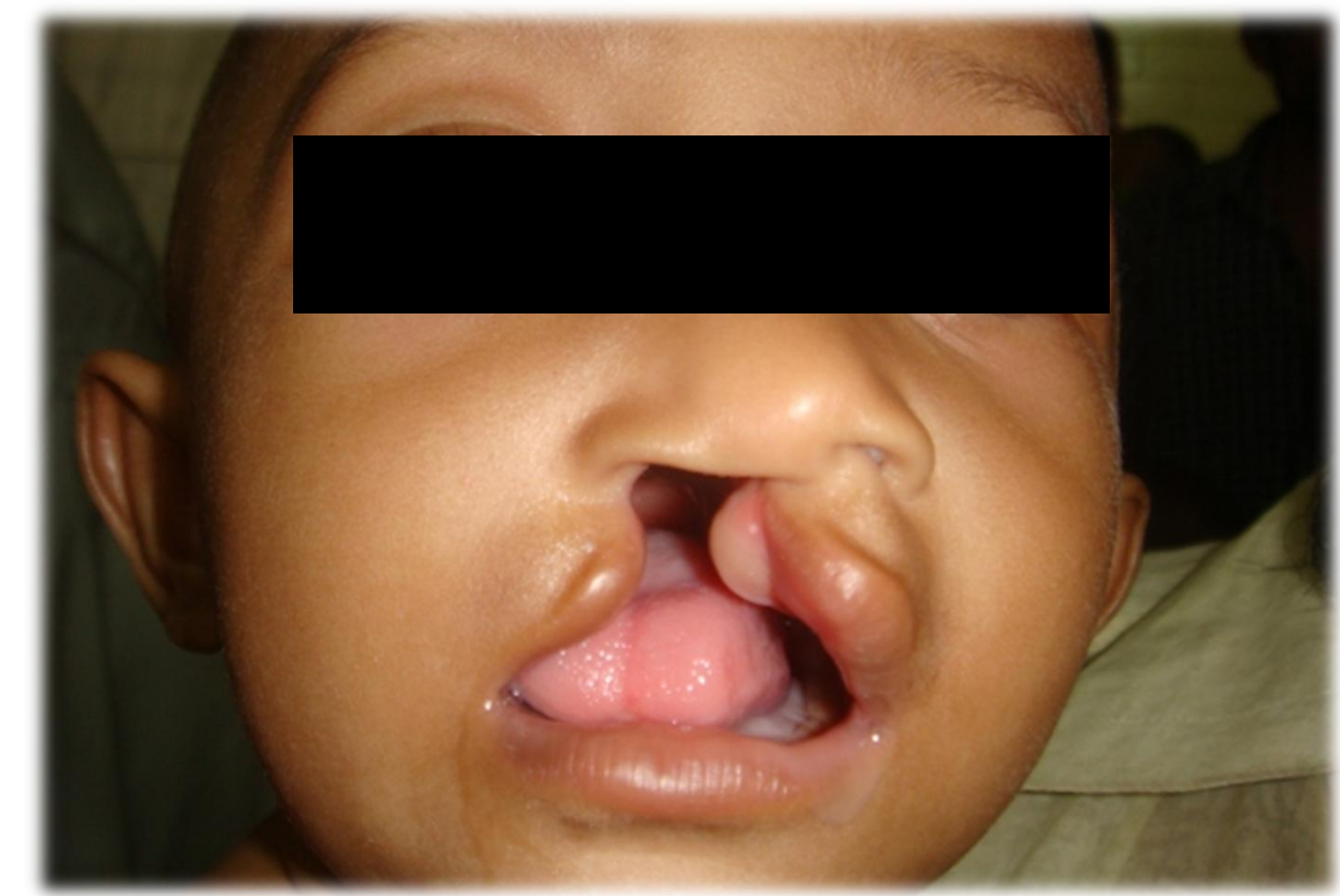Maxillofacial defect can be due to



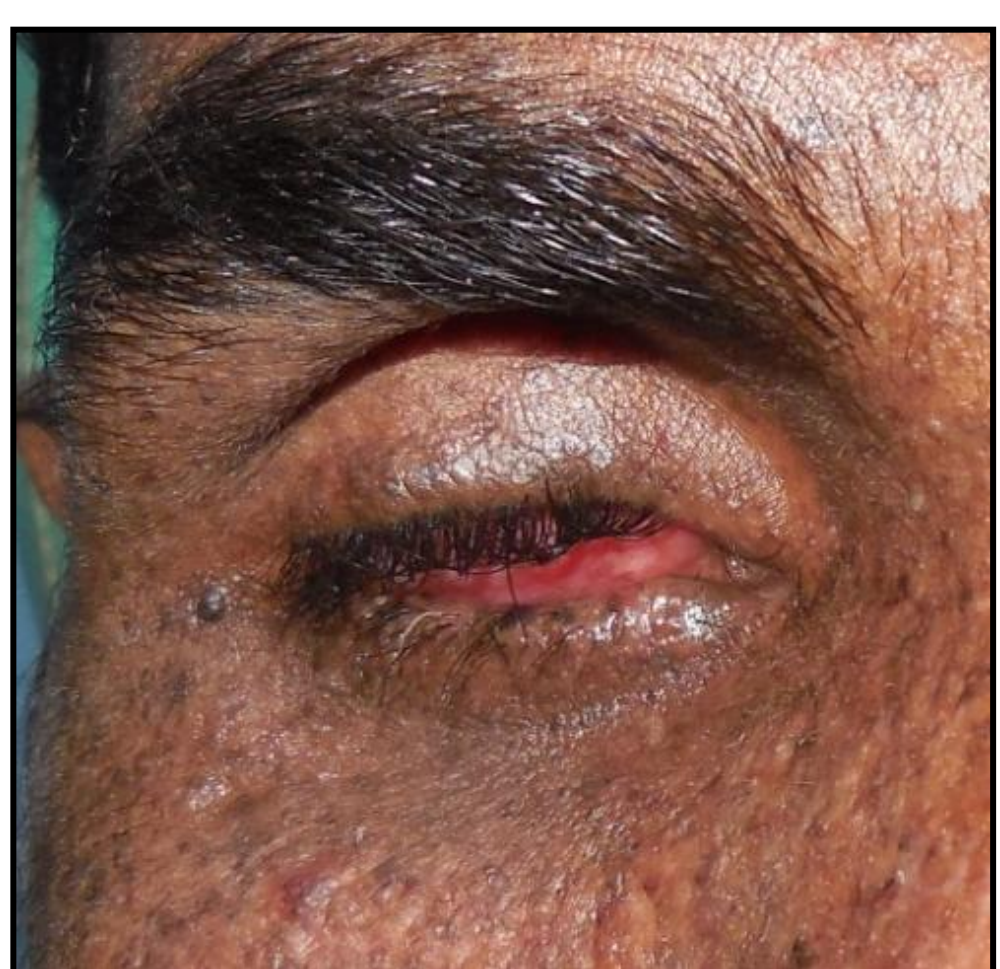Ear defect

Congenital Since Birth

Acquired e.g. Cancer, Fungal, infections, Trauma

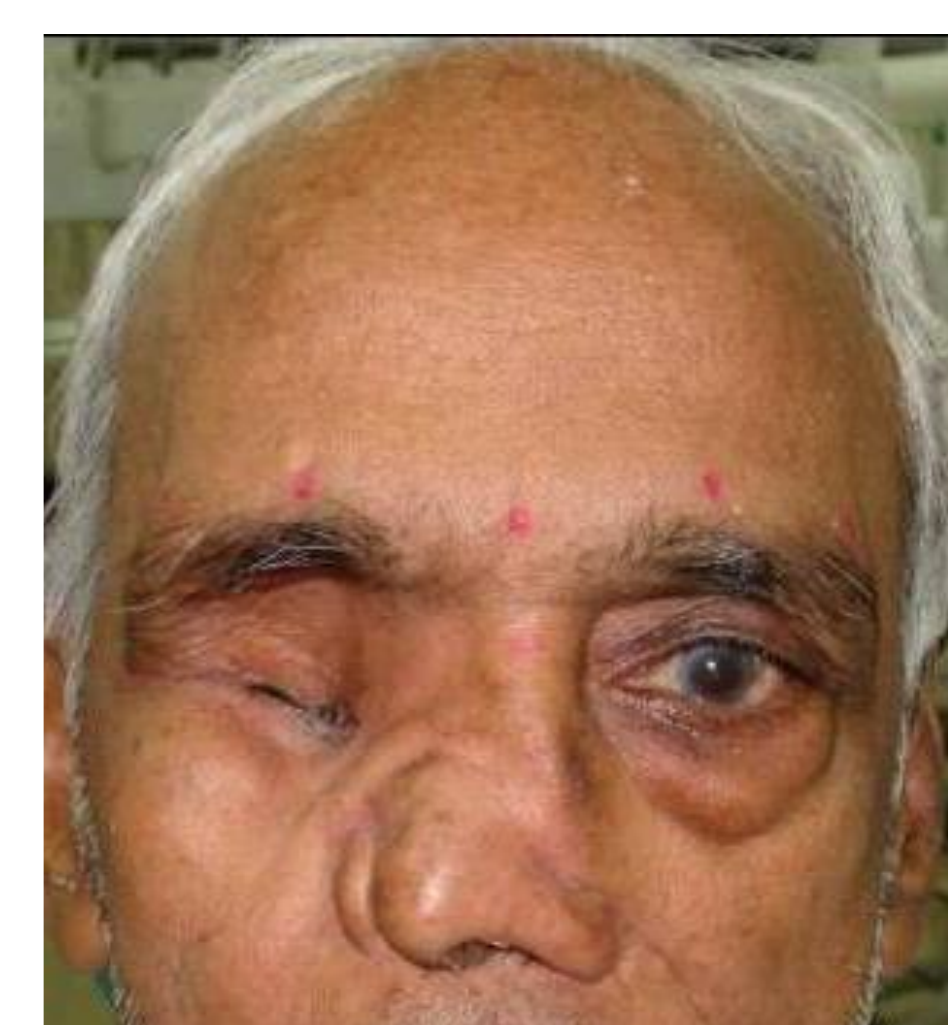

Cleft defect

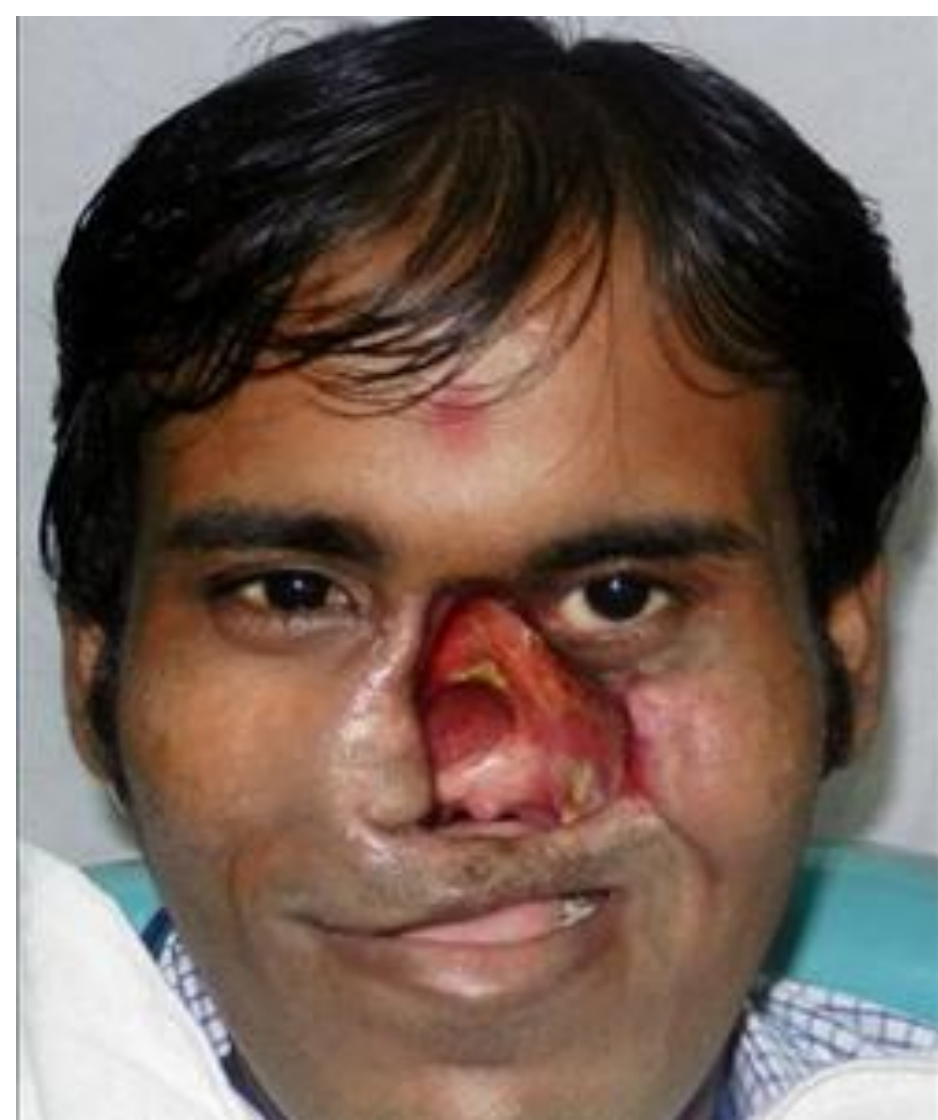

Ocular defect

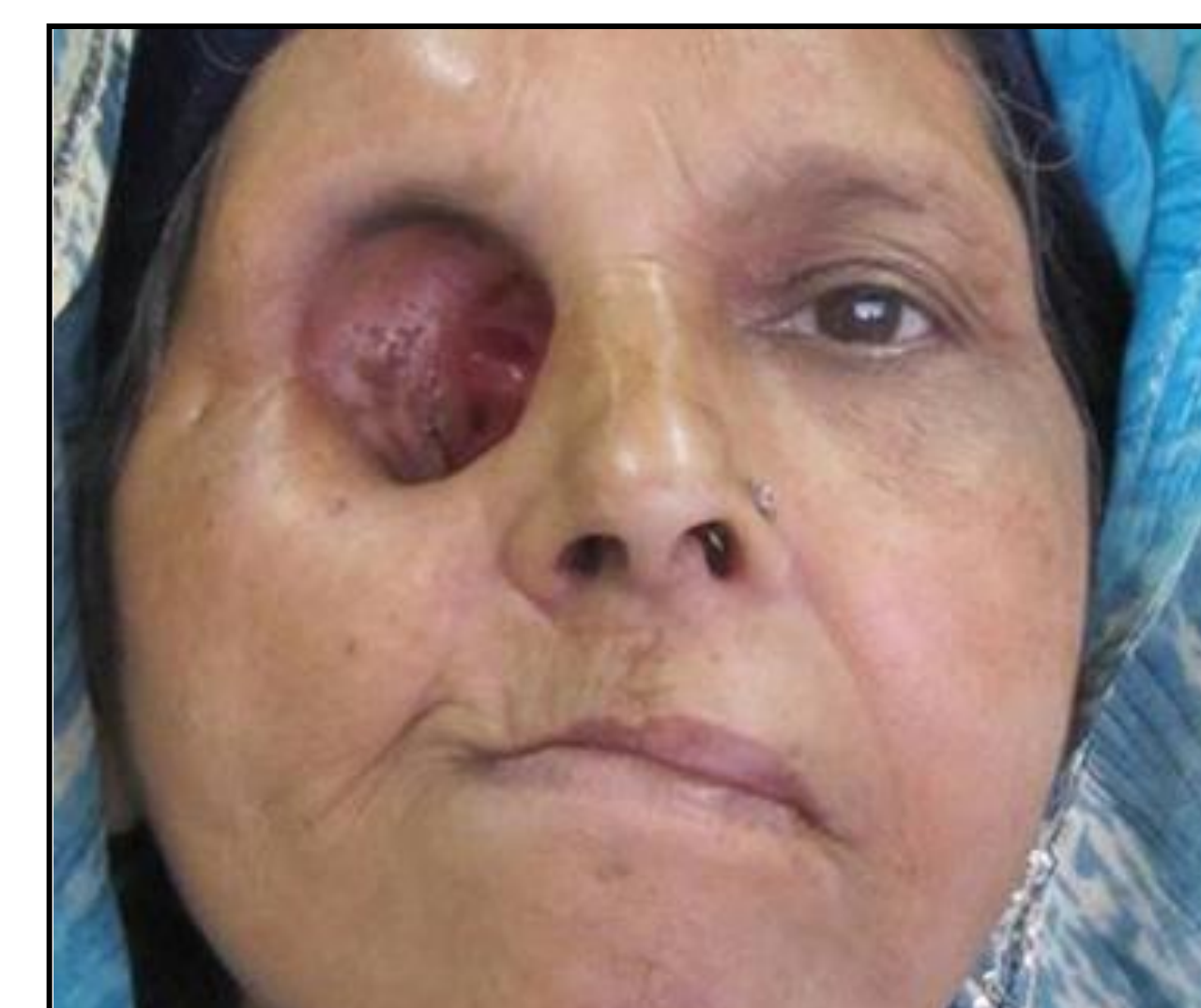Intra oral



Orbital defect



Facial

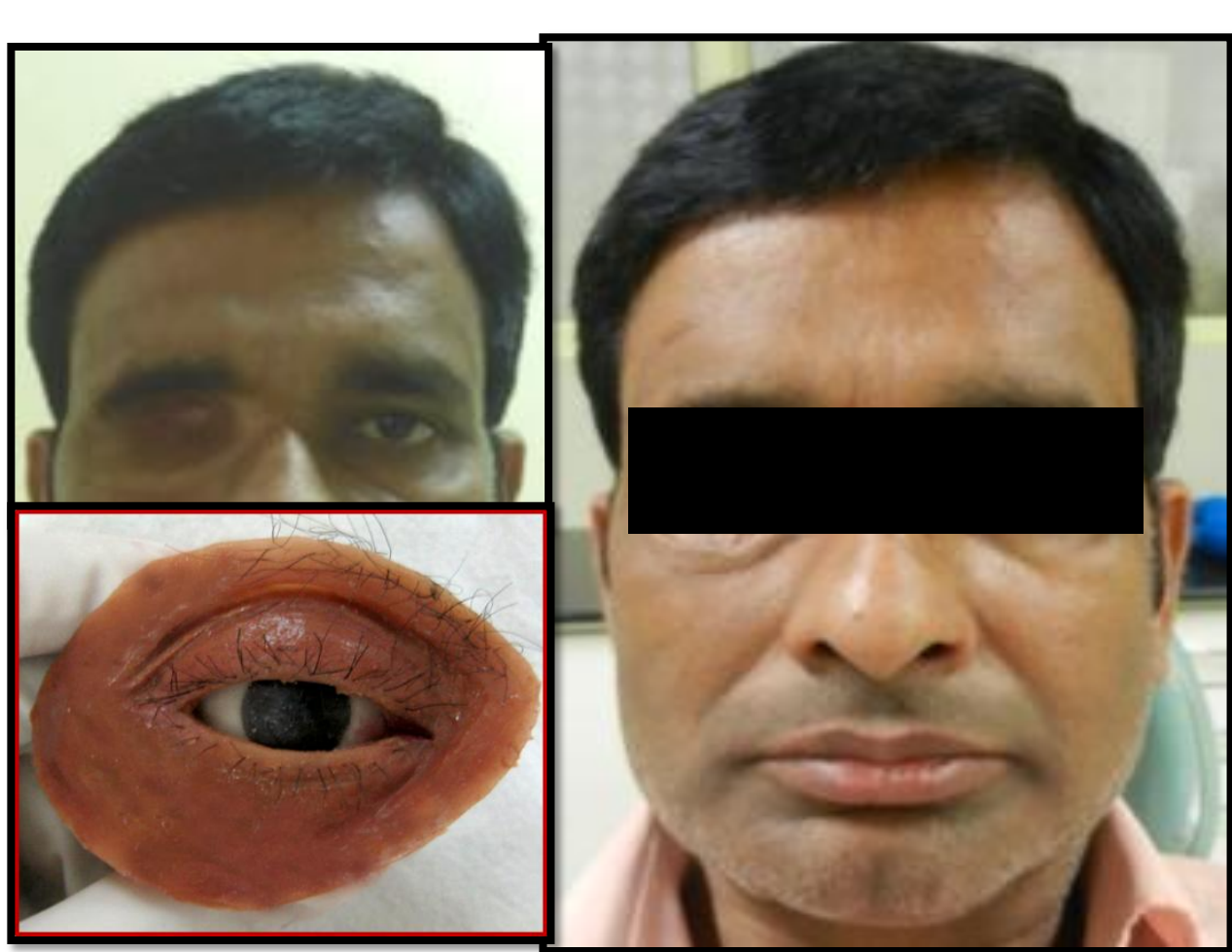

Orbital defect  
Continuous  
with intra oral defect

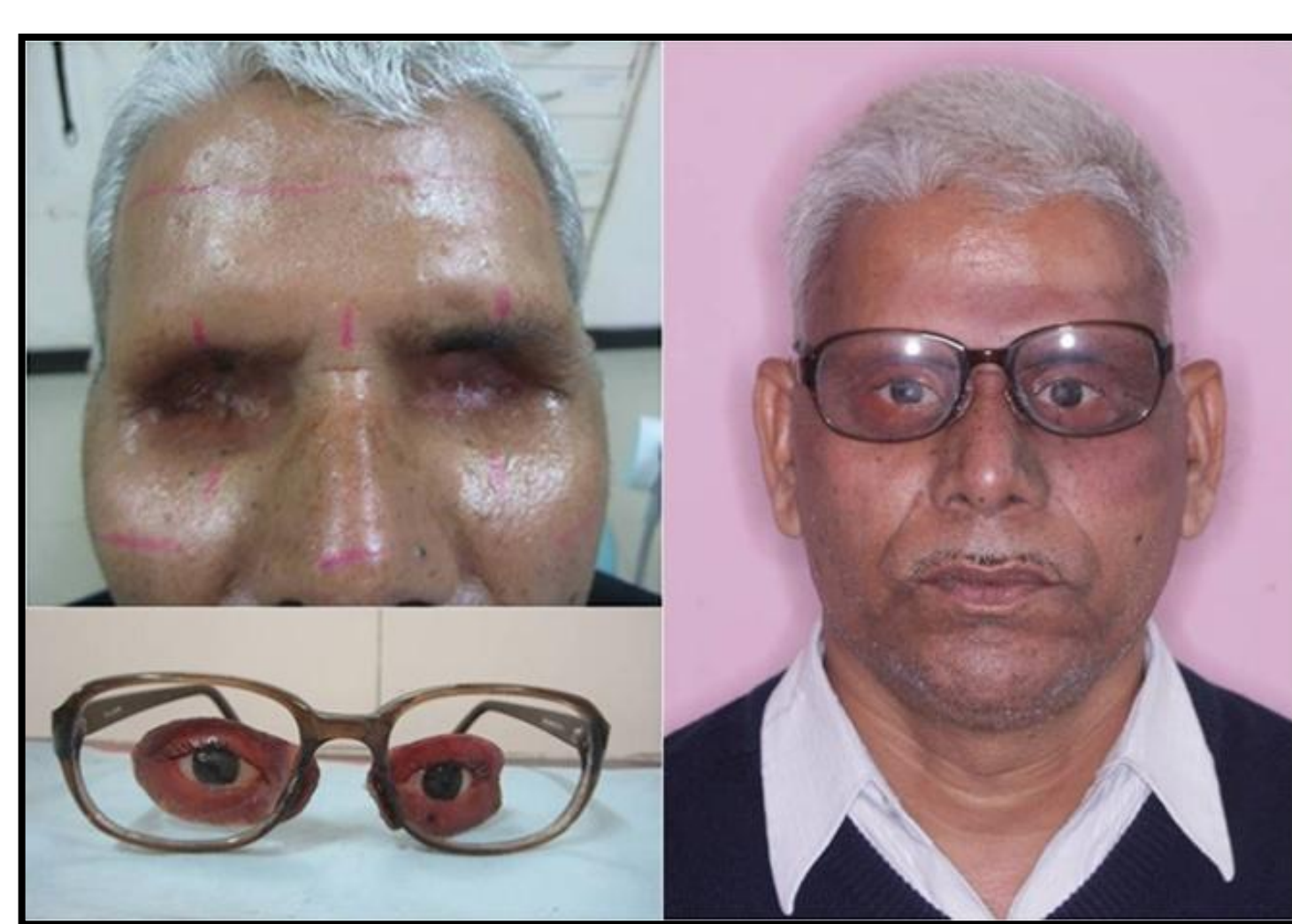Continuous defect

Mid face defect  
Continuous  
with intra oral defect

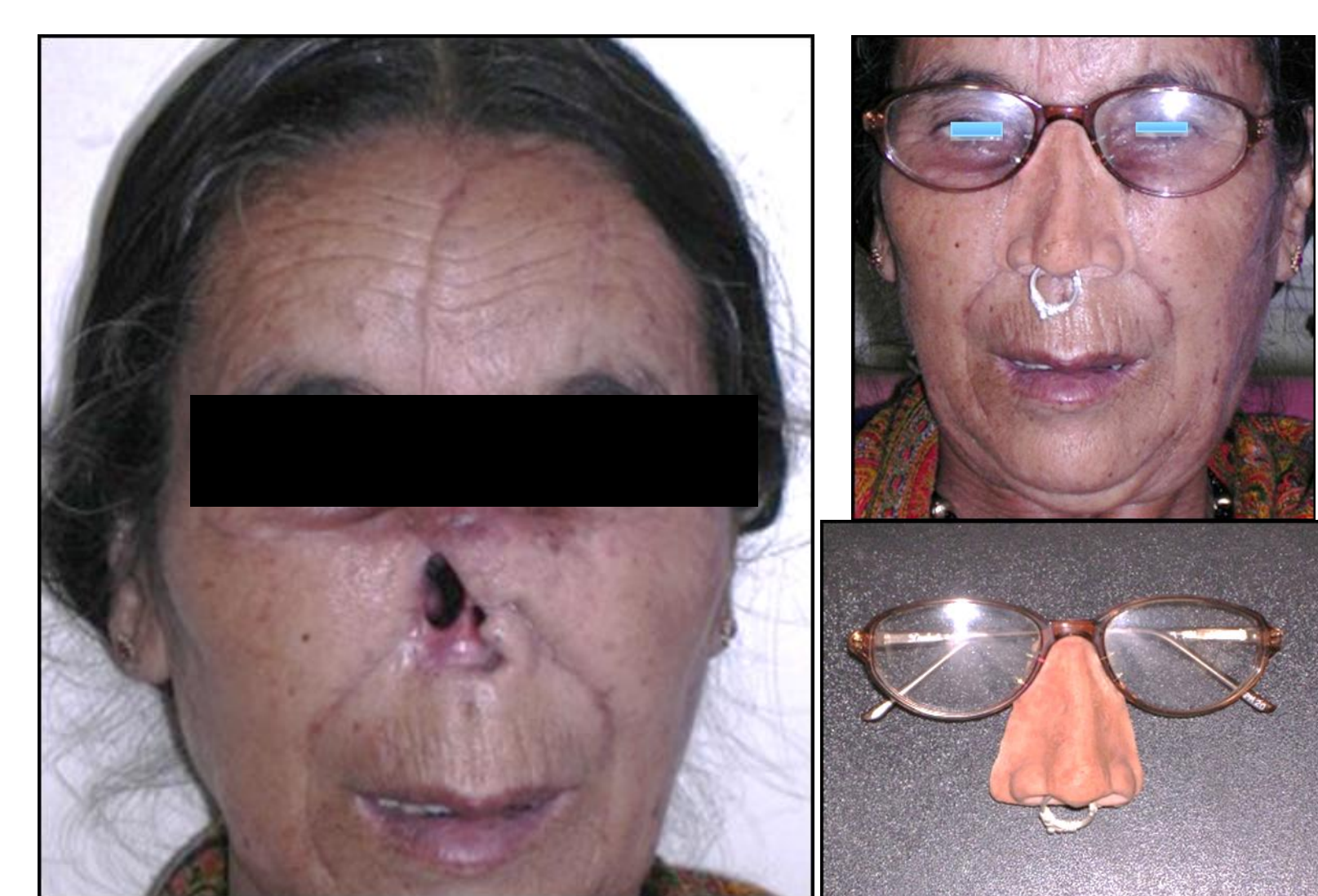## Pre and Post Treatment Photos



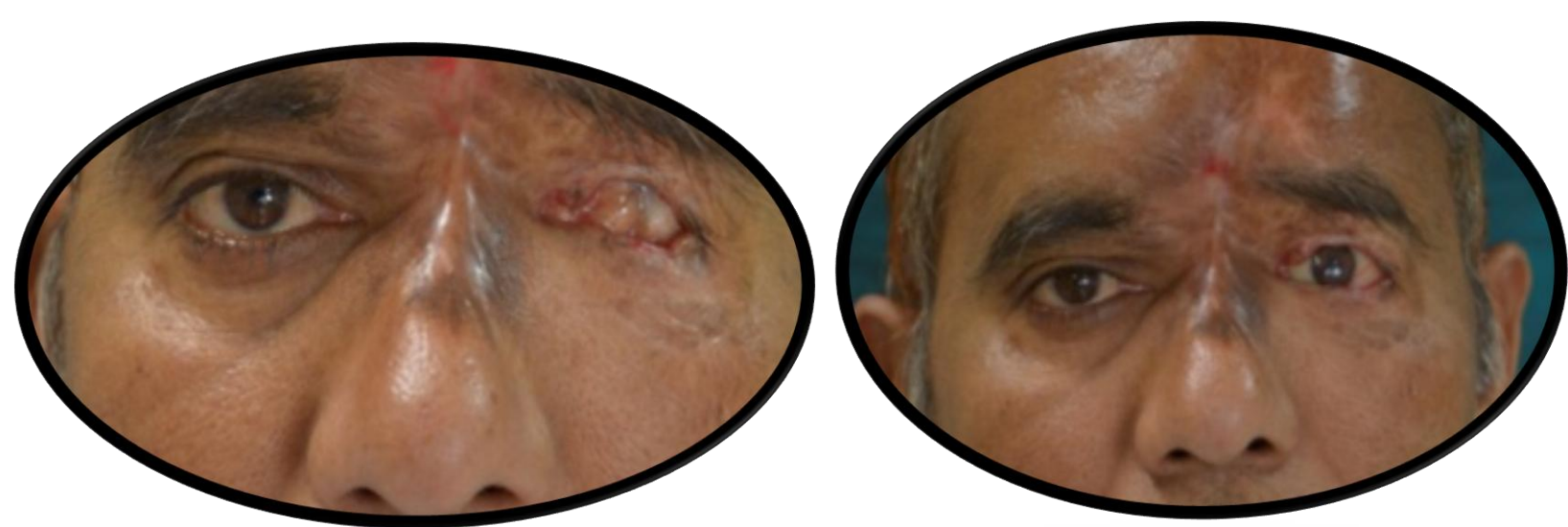
Adhesive retained orbital prosthesis



Spectacle retained orbital prosthesis



Spectacle retained nasal prosthesis



Ocular prosthesis

